

Case Study



# **Integrating BodyWorks Eve © Simulation Systems into Ultrasound Training Programmes**



 BODYWORKS|Eve<sup>®</sup>

*Jane Arezina, Sandra Morrissey and Mike Kirk  
Members of the Medical Ultrasound Team  
University of Leeds*



## About the Authors

Jane Arezina (right), Sandra Morrissey (left) and Mike Kirk (middle) all teach on the Postgraduate Diagnostic Imaging (Medical Ultrasound) suite of programmes at the University of Leeds.

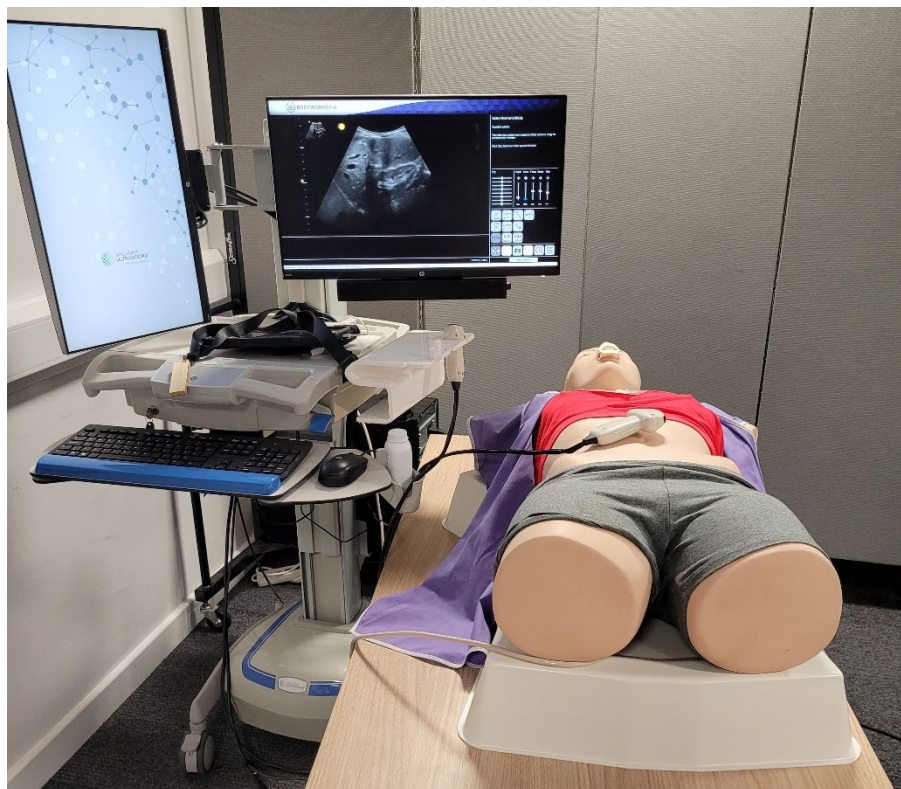
Jane Arezina is an Associate Professor in Medical Ultrasound with a special interest in obstetric ultrasound and delivering unexpected news in this area. She developed the first BSc (Hons) Medical Ultrasound (Sonography) accredited by the Consortium for the Accreditation of Sonographic Education (CASE) which is due to commence in September 2024 and she is also a representative for the Society and College of Radiographers on CASE committee.

Sandra Morrissey is a lecturer in Medical Ultrasound has a special interest in gynaecological ultrasound and is a former member of the Society and College of Radiographers Ultrasound Advisory Group.

Mike Kirk is a lecturer in Medical Ultrasound and the programme leader for the Postgraduate Diagnostic Imaging (Medical Ultrasound) suite of programmes at the University of Leeds. He has a special interest in General Medical Ultrasound and medical ethics.

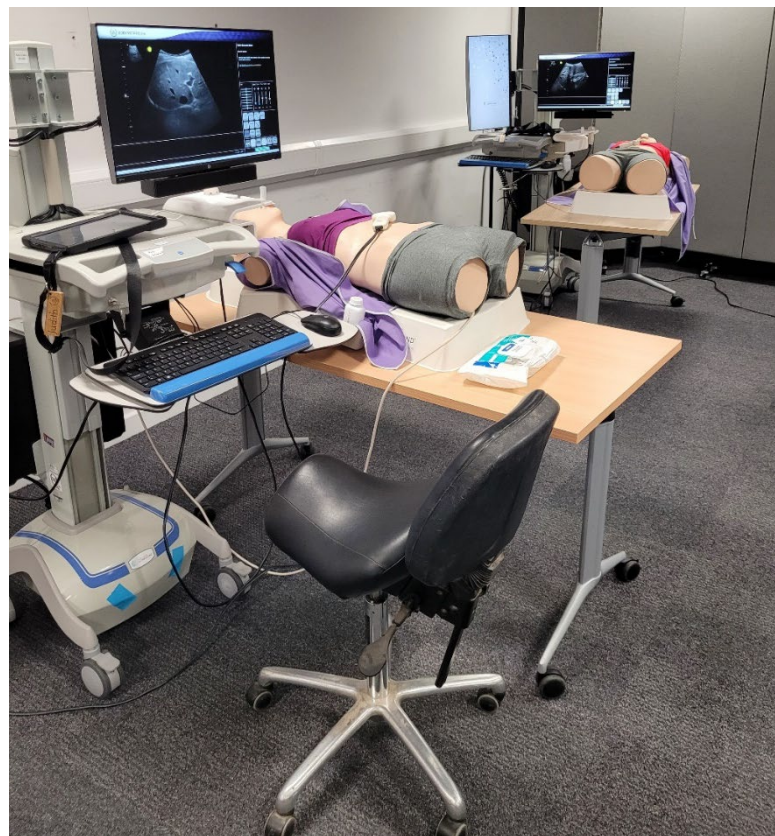## Introduction

Since the COVID pandemic, clinical departments have struggled to provide sufficient ultrasound experience for the increasing number of professionals who need to be trained to undertake ultrasound examinations. One of the main areas of concern, is ensuring that there are enough suitably qualified and competent sonographers to fill vacancies in the clinical setting. Incorporating simulation alongside, and to compliment, the clinical training of students is beneficial, as it is likely to increase patient safety, student confidence, and ultimately, competence to practice. One simulation system is the BodyWorks Eve (BWE), a high-fidelity, ultra-realistic female patient simulator designed to meet the training needs of Point of Care Ultrasound (PoCUS) in Emergency Medicine and Critical Care scenarios. Each system includes a manikin which includes palpable and accurate anatomical landmarks and over 100 real patient cases, which allows students to perform realistic ultrasound examinations. The systems also include ultrasound data for over 10,000 pathology variations across cardiac, lung, transabdominal and pelvic body systems with the facility to create bespoke patient cases with tailored clinical information which are available via Active Scenarios.



The postgraduate (PG) Diagnostic Imaging (Medical Ultrasound) programme at the University of Leeds has incorporated simulation using the BWEs into the training of a wide range of different health care professionals over the past 3 years. The programme owns six (6) BWE systems, which are housed in a dedicated simulation suite situated on campus. A major benefit of the BWE systems is that the functionality is very similar to that of an ultrasound machine, which means that the technique needed to undertake the scan closely replicates scanning real patients in clinical practice. This enables students to gain the essential skills underpinning sonography including anatomy and anatomical relationships, scan planes, ergonomics, probe manipulation and orientation. They also learn the fundamental physical principles of ultrasound and link these to operating the controls and to hand-eye coordination. However, some of the controls or techniques (e.g. colour Doppler) do not have any functionality within some areas of the manikin.

In addition to the BWEs, the simulation suite houses a ScanTrainer (with transabdominal and transvaginal capability), three ultrasound machines, electronic teaching media, and a wide range of ultrasound and Doppler phantoms. The programme also has access to a scan room at a local hospital where students can be taught using real patients.






Utilising the simulation equipment alongside clinical placement activities increases the students' confidence as they are able to gain scanning experience that is not time sensitive, where they can make mistakes without losing face, without the constant presence of a sonographer. However, sessions with experienced sonographers and/or lecturers are also essential to scrutinise and adjust scanning technique and body position with a view to reducing work-related musculoskeletal disorders as the more experience of scanning they gain, the better they become.

Most of the current postgraduate students are novices with limited, or no, formal ultrasound training. On the first day of the programme, all students, regardless of their background, clinical area being studied or how they propose to incorporate the use of medical ultrasound into their practice, undertake a session in the simulation suite focusing on the BWE but also utilising other simulation equipment. This session enables the university staff to ensure that the students have a good, consistent, and evidence-based introduction to fundamental ultrasound techniques. The students subsequently participate in increasingly complex learning events and undergo a formative clinical assessment using the BWE.

### **Introductory session**

Before engaging with the BWEs, students undertake a short introductory session where they are shown how to use the equipment safely (including ergonomics), probe manipulation, the system controls and how structures appear on ultrasound.



### **Clinical specific sessions**

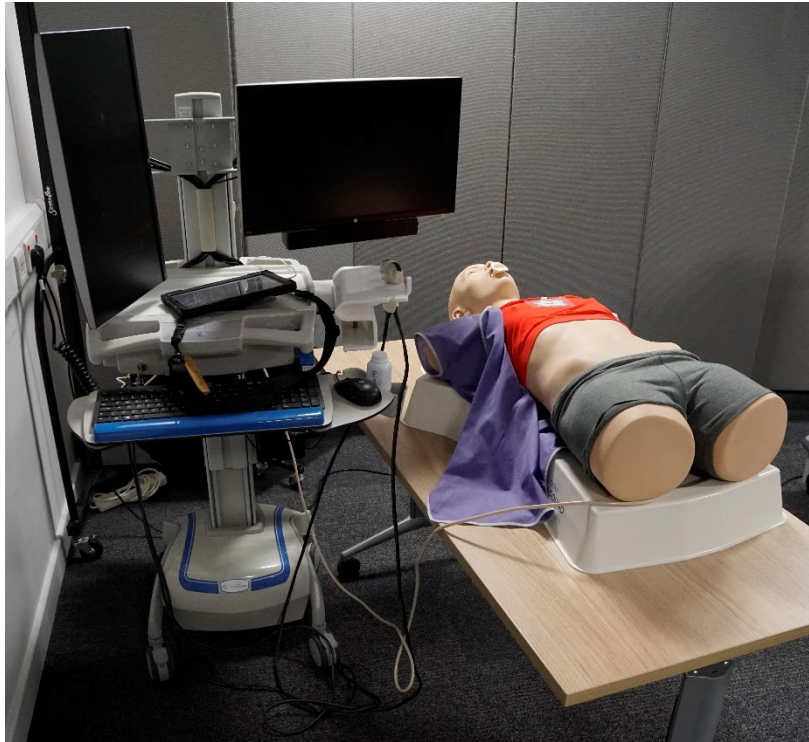
The teaching focuses mainly on abdominal cases and pathology as the BWEs were developed for PoCUS rather than general sonography training and are only amenable to transabdominal (TA) techniques with no capability for transvaginal (TV) examinations. However, the early pregnancy and gynaecological cases are very helpful for teaching TA techniques (such as contralateral scanning), showing the difficulty of locating and identifying ovaries and the TA appearance of pathology, which may be required when patients decline or are unable to have a TV scan.

The BWE allows the tutor to create tailored learning packages for each student group which includes clinical information and the team has allocated a name to each of the systems (named Patricia, Rosie, Dolly, Maggie, Judith and Tessa) and a coloured top to cover their breasts. This makes the manikins appear more realistic and attempts to teach the students the importance of dignity and respect.

The students are split into groups to work through a series of region-specific exercises, supported by one of the tutors, who is a member of the university teaching team. This enables the tutor to identify and support students from the outset and to ensure that they are learning the correct, evidence-based technique. It has the added benefit of peer learning and support.

### **Obstetric and gynaecological ultrasound training**

The aim of the obstetric and gynaecology ultrasound training sessions is to ensure the students are simulator competent to perform an TA gynaecological and an early pregnancy ultrasound examination. Initially, students focus on gaining experience of undertaking normal examinations: this enables them to be able to focus on scan technique and hand-eye coordination. Each session typically takes 2 hours to complete and provides the foundations for safe and competent TA gynaecological and early pregnancy ultrasound practice.



### Session 1

Students are allocated one of the BWE and each of the students undertakes and records images for a full TA pelvic examination with measurements as outlined below:-

1. Obtain longitudinal (LS) section of pelvis – to include bladder, entire uterus, cervix and vagina. Remember to scan through and examine the entire region, out to adnexa and the bladder.
2. Obtain the full-length of the endometrium and measure the thickness (ET). Record your measurement.
3. Obtain transverse (TS) section of pelvis – to include bladder and uterus – remember to scan from fundus to cervix.
4. Locate and obtain a transverse section of right ovary- remember to scan out to visualise the entire right adnexa.
5. Locate and obtain longitudinal section of right ovary- remember to scan out to visualise the entire right adnexa.
6. Split the screen and measure the right ovary in 3 planes and calculate the volume.
7. Locate and obtain transverse section of left ovary- remember to scan out to visualise the entire left adnexa.

8. Locate and obtain longitudinal section of left ovary- remember to scan out to visualise the entire left adnexa.
9. Split the screen and measure the left ovary in 3 planes and calculate the volume.

Students are required to complete the worksheet.

## Normal gynaecology work sheet

Area	Measurement	Volume
ET		
Right ovary		
Left Ovary		

Once each of the students has completed the first task, the tutor adds an 11-week intra-uterine pregnancy to the BWEs. Students then undertake and record images for an early pregnancy scan as follows: -

1. Obtain longitudinal (LS) section of pelvis – to include bladder, entire uterus, cervix and vagina. Remember to scan through and examine the entire region, out to adnexa and the bladder.
2. Obtain a transverse section of pelvis – to include bladder and uterus – remember to scan from fundus to cervix.
3. Identify a fetal pole/fetus if present and obtain a crown-rump length (CRL)
4. Locate and obtain a transverse and longitudinal sections of right ovary- remember to scan out to visualise the entire right adnexa.
5. Locate and obtain transverse and longitudinal sections of Left ovary- remember to scan out to visualise the entire left adnexa.

Once the students have completed this case, the tutor adds the 6-week intra-uterine pregnancy and the students repeat the scan as above. They record their findings in the table below: -

## Early pregnancy work sheet

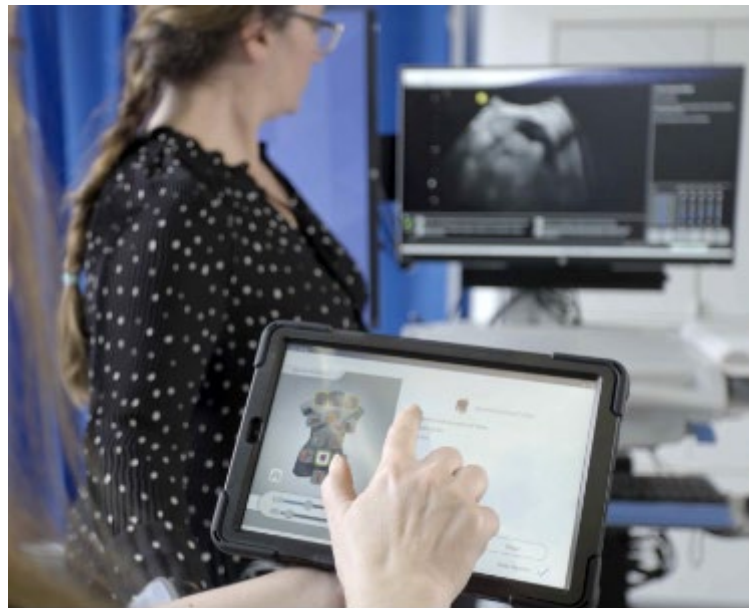Case	CRL	Gestation
Case 1		
Case 2		



## Session 2

The next sessions involve the more complex gynaecological cases where students must detect and identify pathology. Each group of students is allocated one of the BWEs, each of which is pre-installed with one of the following gynaecology cases:-

1. Small pelvic mass
2. Large pelvic mass
3. Free fluid - mild
4. Free fluid - moderate
5. Free fluid - severe
6. Free fluid – complex



Each BWE is allocated a clinical history to encourage the students to consider this and other demographic details (such as age/gender) before commencing each of the examinations. The tablet is removed to ensure that the students are not aware of the pathology in each of the BWEs. Each group works together to scan, interpret and report the examination on their BWE case before rotating to each of the other BWEs in turn. Instructions to students: -

1. Undertake scan using a systematic approach and record images as required.
2. Identify and measure any pathology. Note location and relationship to other organs.
3. Check for fluid and masses.
4. Write a description of your findings.
5. Extend the examination where appropriate (e.g., scan the kidneys).
6. Consider other US techniques that you would like to use e.g., TV/Doppler.

7. Write a report with a conclusion using the template below: -

## Ultrasound Report

Patient ID

Clinical information

Report

Conclusion

Scanned by

Date

At the end of the session, the tutor provides the expected in answers (EiA) for each of the cases and the students compare their findings, images and report with the EiAs, reflect on their findings, ask questions of the tutor/fellow students and discuss aspects that they found challenging.

### Session 3

The next sessions involve the more complex early pregnancy cases where students must detect and identify the complications as follows: -

1. Ectopic pregnancy left adnexa
2. Ruptured ectopic pregnancy left adnexa
3. Ectopic pregnancy right adnexa
4. Ruptured ectopic pregnancy right adnexa
5. Early pregnancy, no gestational sac

Each BWE is allocated a clinical history to encourage the students to consider this and other demographic details (such as age/gender) before commencing each of the examinations.

The tablet is removed to ensure that the students are not aware of the pathology in each of the BWEs. Each group works together to scan, interpret, record images (as required) and report the examination on their BWE case before rotating to each of the other BWEs in turn.

Instructions to students: -

1. Undertake scan using a systematic approach.
2. Identify and measure any pathology. Note location and relationship to other organs.

3. Check for fluid and masses.
4. Write a description of your findings.
5. Extend the examination where appropriate (e.g., scan the kidneys).
6. Consider other US techniques that you would like to use e.g., TV/Doppler.
7. Write a report with a conclusion using the template below: -

## Ultrasound Report

Patient ID

Clinical information

Report

Conclusion

Scanned by

Date

At the end of the session, the tutor provides the expected in answers (EiA) for each of the cases and the students compare their findings, images and report with the EiAs, reflect on their findings, ask questions of the tutor/fellow students and discuss aspects that they found challenging.

### Limitations

Performing a TA scan on the BWE differs from clinical practice, in that the students do not have to consider bladder filling or patient discomfort. In addition, although students can alter the equipment settings, these do not improve resolution which is a crucial factor particularly when attempting to correctly locate ovaries on a TA scan. TV techniques are taught using the ScanTrainer® and the transvaginal ultrasound phantoms, which are used alongside the BWEs.

## **Abdominal (GM) ultrasound training**

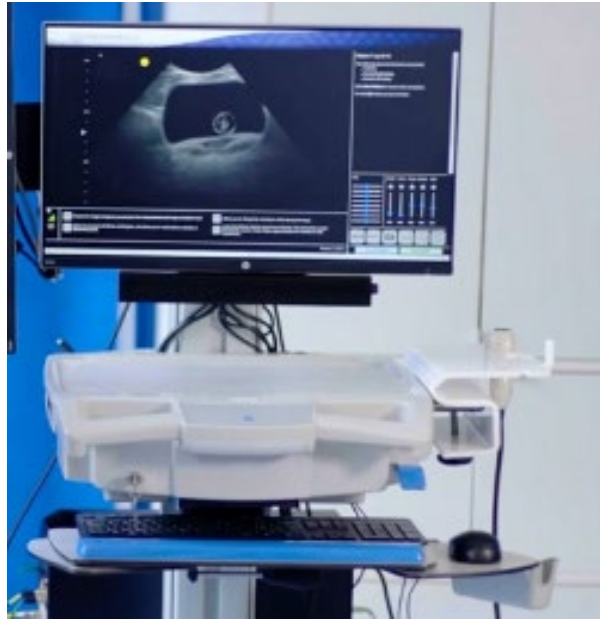The range and scope of cases for the abdominal body systems is vast and enables tutors to utilise the BWE systems for a huge number of learning and training opportunities. The aim of the GM ultrasound training sessions is to ensure they are simulator competent to perform a wide range of GM ultrasound examinations.

### **Session 1**

This is a tutor-led session with one tutor using the BWE, connected to a large display monitor, which enables all the students to view the images on the screen. The tutor performs a normal upper abdominal examination using a systematic approach whilst another tutor asks the student to identify the anatomy, the anatomical landmarks and the scan plane for each organ/body system as outlined below:-

1. Aorta
2. Pancreas
3. Liver
4. Gall bladder
5. Bile ducts
6. Right kidney
7. Spleen
8. Left kidney
9. Urinary bladder

The tutors will also discuss ergonomics, equipment settings, adaptations of technique (e.g. moving the patients position to right anterior oblique (RAO) or using colour Doppler) and the images to record plus annotating those images.



This session typically takes 2 hours to complete and provides the student with the underpinning principles of abdominal scanning.

## Session 2

Students are allocated one of the BWE and each of the students undertakes and records images for a full abdominal examination with measurements as outlined below:-

1. Obtain longitudinal (LS) and transverse (TS) sections of the organs/body systems/vessels 1-9. Remember to scan through and examine the entire organ/vessel.
2. Measure the following:- Aorta (TS), common bile duct (CBD) (LS), both kidneys (LS) and spleen (LS). Record your measurements.
3. Split the screen and measure the urinary bladder in 3 planes and calculate the volume.

Students are required to complete the worksheet below.

## Normal abdominal work sheet

Area	Measurement	Volume
Aorta		
Bile ducts		
Right kidney		
Spleen		
Left kidney		
Urinary bladder		



Sessions 1 and 2 provide students with the foundations for safe and competent GM ultrasound practice.

It is possible to adjust the level of the rib shadows and initially, these are removed completely to aid the students. However, as the students become more proficient, it is better to set the rib shadows to a more realistic level to reflect real patients.

### **Session 3**

The students are allocated one of the BWEs, each of which is pre-installed with one pathology in a different body system by the tutor. Each BWE is allocated a clinical history to encourage the students to consider this and other demographic details (such as age/gender) before commencing each of the examinations. The tablet is removed to ensure that the students are not aware of the pathology in each of the BWEs. Each group works together to scan, interpret, record images as required and report the examination on their BWE case before rotating to each of the other BWEs in turn. Examples of pathology include:-

#### **Aorta**

- Small, medium and large fusiform aneurysm
- Saccular aneurysm
- Dissecting aneurysm

#### **Renal and genitourinary (GU)**

- Calculus/ multiple calculi in the right kidney
- Moderate hydronephrosis in the right kidney and a large pelvic mass
- Mild/moderate/sever hydronephrosis in the right kidney
- Calculus in the left kidney
- Moderate hydronephrosis with a calculus in the right kidney
- Severe hydronephrosis with a pelvic ureteric junction(PUJ) Obstruction in the right kidney
- Renal cell carcinoma in the right kidney

#### **Hepato-biliary**

- Pancreas mass
- Contracted gall bladder
- Gall bladder calculus

- Calculus and acalculous cholecystitis
- Adenomyomatosis
- Dilated common bile duct
- Dilated common bile duct with calculus
- Liver metastases

Instructions to students: -

1. Undertake and record images for a full abdominal ultrasound examination using a systematic approach.
2. Identify and measure any pathology. Note location and relationship to other organs.
3. Check for fluid and masses.
4. Write a description of your findings.
5. Extend the examination where appropriate (e.g. scan the bladder).
6. Consider other US techniques that you would like to use e.g. Colour Doppler/patient position
7. Write a report with a conclusion using the template below: -

## Ultrasound Report

Patient ID

Clinical information

Report

Conclusion

Scanned by

Date

At the end of the session, the tutor provides the expected in answers (EiA) for each of the cases and the students compare their findings, images and report with the EiAs, reflect on their findings, ask questions of the tutor/fellow students and discuss aspects that they found challenging.

Due to the number of body systems and pathologies available, students require a number of sessions to complete all the examinations. Sessions are typically limited to 2 hours in duration.

#### **Session 4**

The students are allocated one of the BWEs, each of which is pre-installed with either a complex case, trauma or chest and lung pathology (see lists below) by the tutor. Each BWE is allocated a clinical history to encourage the students to consider this and other demographic details (such as age/gender) before commencing each of the examinations. The tablet is removed to ensure that the students are not aware of the pathology in each of the BWEs. Each group works together to scan, interpret, record images and report the examination on their BWE case before rotating to each of the other BWEs in turn. Examples of pathology include:-

#### **Complex cases**

- Mild fluid in Morison's pouch and moderate fluid in the left subphrenic space
- Severe fluid in Morison's pouch, moderate fluid in the pouch of Douglas, and severe fluid in the right subphrenic space
- Moderate fluid in Morison's pouch, and severe fluid in the pouch of Douglas
- Mild fluid in the left subphrenic space, mild fluid in the splenorenal space, and moderate fluid in the pouch of Douglas
- Mild right pleural effusion, mild left pleural effusion, and pelvic mass
- Moderate right pleural effusion, moderate left pleural effusion, and pelvic mass
- Severe right pleural effusion, severe left pleural effusion, and pelvic mass
- Mild right pleural effusion, mild left pleural effusion, liver metastases and pelvic mass
- Moderate right pleural effusion, moderate left pleural effusion, liver metastases and pelvic mass
- Severe right pleural effusion, severe left pleural effusion, liver metastases and pelvic mass
- Mild fluid in Morison's pouch, decidualized endometrium, and fluid in the pouch of Douglas

- Mild fluid in Morison's pouch and ruptured ectopic pregnancy

### **Trauma and Chest and lung**

- Mild/moderate/severe fluid in the right subphrenic space
- Mild/moderate/severe fluid in Morison's pouch
- Mild/moderate/severe fluid in the left subphrenic space
- Mild/moderate/severe fluid in the splenorenal space
- Mild/moderate/severe fluid in the pouch of Douglas
- Mild/moderate/severe complex fluid in the right subphrenic space
- Mild/moderate/severe complex fluid in Morison's pouch
- Mild/moderate/severe complex fluid in the left subphrenic space
- Mild/moderate/severe complex fluid in the left splenorenal space
- Mild/moderate/severe complex fluid in the pouch of Douglas

Instructions to students: -

1. Undertake and record images for a full ultrasound examination using a systematic approach.
2. Identify and measure any pathology. Note location and relationship to other organs.
3. Check for fluid and masses.
4. Write a description of your findings.
5. Extend the examination where appropriate
6. Consider other US techniques that you would like to use e.g. Colour Doppler/patient position
7. Write a report with a conclusion using the template below: -

## **Ultrasound Report**

Patient ID

Clinical information

Report

Conclusion

Scanned by

Date

At the end of the session, the tutor provides the expected in answers (EiA) for each of the cases and the students compare their findings, images and report with the EiAs, reflect on their findings, ask questions of the tutor/fellow students and discuss aspects that they found challenging.

Due to the number of body systems and the complex nature of the cases, pathologies available, students require a number of sessions to complete all the examinations. Sessions are typically limited to 2 hours in duration.

### **Use of BodyWorks Eve in Assessment of clinical practice**

The BWE can also be used to formatively assess the students' progress and to provide timely feedback before they undertake any assessments in clinical practice. This also allows parity across the student cohort, as, unlike in clinical practice the tutor can control the working environment and ensure that the student is assessed on a pathological case. This allows a direct comparison of each individual student's technique, ability to recognise anatomy (normal and pathological) and formulate an accurate report.

### **Advantages of using the BodyWorks Eve Simulator**

- The clinical cases enable the students to gain underpinning knowledge of the relevant anatomy and ultrasound techniques necessary to perform an ultrasound examination prior to their first contact with patients.
- Ability to record and review images
- Not limited by time as in the clinical setting where access to machines is limited and ALARA has to be considered.
- Improves student confidence.
- Reduces the need for volunteers to be scanned during teaching sessions as many students do not wish to be scanned in front of their peers.
- It also allows the tutor to identify those students who need extra support, very early in their education and much earlier than with traditional ultrasound teaching methods thus allowing appropriate support mechanisms to be put in place in a timely manner.



- Students have the opportunity to scan cases with pathology they may not see in clinical practice and discuss their findings immediately rather than having to delay the conversation until the patient isn't present.
- Opportunity to discuss image optimisation such as focus, zoom and reducing sector width, even though the BWE images are not improved by adjusting these settings.

### **Disadvantages of using the BodyWorks Eve Simulator**

- Some of the controls on the BWE do not work in the way they do in practice. For example, reducing the depth reduces the size of the image.
- Colour Doppler function and other controls have no functionality
- Some pathologies are not 'real' and are not a true representation of the pathology on ultrasound.
- The functions do not always improve the image quality.
- Ideally, it would be helpful to have technicians to support the tutors and students.

### **Top Tips**

The Introductory sessions are essential prior to the students using the BWE for the first time to ensure that the students use the equipment safely. BWE is an expensive simulator and students need to use it appropriately so that they do not damage it!

The introductory session enables the tutor to introduce underpinning knowledge, such as ultrasound image orientation, probe manipulation, anatomy and examination technique to ensure that the student has a solid foundation for their future learning.

It is ideal to have a dedicated simulation room with a robust booking system which enables the students to engage with the simulators and reserve a time which suits them.

Whenever possible, offer supervised sessions to ensure that the students get the most benefit from the BWE. This will ensure that students are performing scans according to evidence-based best practice.

Ensure the students have an ergonomically safe environment. BWE has the same (or more) issues than ultrasound machines and you need to ensure that the equipment is placed safely and the students have access to height adjustable chairs.

## Conclusion

BWE is an excellent resource, which should be incorporated into the delivery of present and future ultrasound education as it supplements clinical practice experience. Traditional methods of ultrasound education require a large amount of time scanning real patients in the clinical setting which is increasingly difficult for departments to manage. The active scenarios allow the students to identify anatomy and practise techniques in a safe environment to ensure their time in clinical practice is a positive experience.

The BWE can provide the student with the underpinning probe manipulation skills and knowledge necessary for safe ultrasound practice, safeguarding service users and the health care professionals supervising the examination. It also helps tutors to identify students who are struggling with the essential concepts required to perform ultrasound examinations early and plan necessary interventions.

The BSc (Hons) Medical Ultrasound (Sonography) programme at the University of Leeds became the first BSc to be approved by the Consortium for the Accreditation of Sonographic Education (CASE) when it was validated in August 2023. The simulation equipment and suite were instrumental in the development of this undergraduate (UG) programme which will recruit students from September 2024. In year one, most of the clinical practice will be undertaken using simulation (14 weeks of the 18 weeks of clinical experience), which will ensure that the students have the hand-eye coordination, underpinning anatomy and technical knowledge and communication skills required prior to being placed in clinical departments.

